

Using Machine Learning tools to Calculate Multi Slice Multi Echo (MSME) Score for Alzheimer's Diagnosis

Sreedhar Yalamati

Solutions Architect, Celer Systems Inc., Technology Services, CA, USA,0009-0009-4504-1467

¹Received: 12 October 2023; Accepted: 26 December 2023; Published: 09 January 2024

ABSTRACT

Alzheimer's disease (AD) poses a significant public health challenge. The hippocampus is one of the most affected brain regions and a readily accessible biomarker for diagnosis through MRI imaging in machine learning applications. However, utilizing entire MRI image slices in machine learning for AD classification has shown reduced accuracy. This study introduces the novel 'select slices' method, which involves identifying and focusing on specific landmarks within the hippocampus region in MRI images. This approach aims to improve classification accuracy by eliminating irrelevant information from the analysis.

Our research aims to identify which views of MRI images produce higher accuracy for AD classification. We used multiclass classification using the publicly available Alzheimer's Disease Neuroimaging Initiative (ADNI) dataset, utilising Resnet50 and LeNet models to evaluate the value of three specific views (sagittal, coronal, and axial) and categories (normal, mild, and severe AD). The dataset comprised 4,500 MRI slices across these three views and categories.

Our findings unequivocally demonstrate that the 'select slices' approach surpasses the use of entire slices in MRI images for AD classification. Specifically, our method elevates machine learning accuracy, with the coronal view showcasing exceptional performance. This methodology is a game-changer in improving the accuracy of machine learning models for AD classification, with results closely mirroring those of medical experts, the gold standard for AD diagnosis. Moreover, we observed that LeNet models hold great promise as effective tools for AD classification.

INTRODUCTION

Alzheimer's disease (AD) stands as a pressing concern in public health, with approximately 44 million cases worldwide, a figure projected to soar to 131.5 million by 2050. This neurodegenerative ailment primarily afflicts individuals aged 65 and above, impairing memory and cognitive function. While AD lacks a definitive cure, certain medications and treatments can alleviate symptoms temporarily or slow its progression. Early diagnosis significantly eases the management of the condition.

Early detection hinges on monitoring and investigating brain deterioration before AD advances. The hippocampus, a pivotal brain region, is a notable biomarker for AD due to its susceptibility to degeneration, particularly impacting memory. Magnetic resonance imaging (MRI) facilitates detecting hippocampal volume changes, aiding AD diagnosis. With its advanced imaging capabilities, MRI plays a pivotal role in analysing structural brain alterations.

Advancements in machine learning have propelled the development of models capable of diagnosing AD based on MRI scans. These models excel in deciphering intricate patterns from MRI images, offering swift and accurate diagnoses. Leveraging machine learning expedites diagnosis compared to manual methods, ensuring consistency across vast datasets. Multiclass classification, distinguishing AD into three categories (AD, Mild Cognitive Impairment (MCI), and Normal Control (NC)), proves beneficial in capturing subtle disease progression nuances.

¹ How to cite the article: Yalamati S., January 2024; Using Machine Learning tools to Calculate Multi Slice Multi Echo (MSME) Score for Alzheimer's Diagnosis; *International Journal of Innovations in Scientific Engineering*, Jan-Jun 2024, Vol 19, 1-12

Various strategies have been proposed to enhance AD classification accuracy, including improving MRI image quality, employing segmentation, and utilizing classification techniques such as AdaBoost. Selecting specific MRI slices rather than analysing entire datasets has shown promise in enhancing classification accuracy. Despite lacking detailed methodologies, this approach, mainly focusing on hippocampal landmarks, presents a simplified and potentially more effective means of AD diagnosis.

Medical experts' insights and experiences are crucial in identifying biomarkers for early AD diagnosis, particularly concerning the hippocampus. Utilizing their expertise as ground truth aids in AD classification across different MRI views. While axial, coronal, and sagittal views offer complementary features, focusing on a single view streamlines the diagnostic process.

The proposed method of selecting MRI slices based on hippocampal landmarks holds the potential for improving AD classification performance. Comparing this approach with traditional methods involving entire MRI slices can validate its efficacy. Furthermore, investigating which MRI views yield higher accuracy in AD classification informs future diagnostic strategies. Multiclass classification further refines the diagnosis, facilitating tailored interventions for individuals at different AD stages.

LITERATURE REVIEW

Single-Modal Data and Traditional Machine Learning Models:

In their study, C. Kavitha et al. [58] explored various machine learning (ML) models such as Decision Trees (DT), Random Forests (RF), Support Vector Machines (SVM), XGBoost, and a voting classifier, employing different Feature Selection (FS) techniques on the OASIS dataset. Notably, RF and XGBoost exhibited superior accuracy. Similarly, another study [38] conducted on the same dataset compared SVM, Logistic Regression (LR), DT, and RF for Alzheimer's disease prediction, with SVM demonstrating notable performance. Further, researchers [59] utilized the Hybrid Feature Selection Model (CHFS) on a medical dataset to identify optimal features, followed by implementing stacked ML models, which led to enhanced accuracy. Additionally, SVM, RF, and Gradient Boosting (GB) were employed in [60] to predict the transition from Mild Cognitive Impairment (MCI) to Alzheimer's Disease (AD), with RF showing the highest performance. RF was also applied in [61] to predict MCI to AD transition using balanced data from ADNI and SVM Decision Trees (DT) in [62] to distinguish between AD and MCI patients. Furthermore, SVM was utilized in [63] to detect AD utilizing MRI, PET, and SPECT data, while RF was applied in [64] to demographic and genetic data for AD prediction.

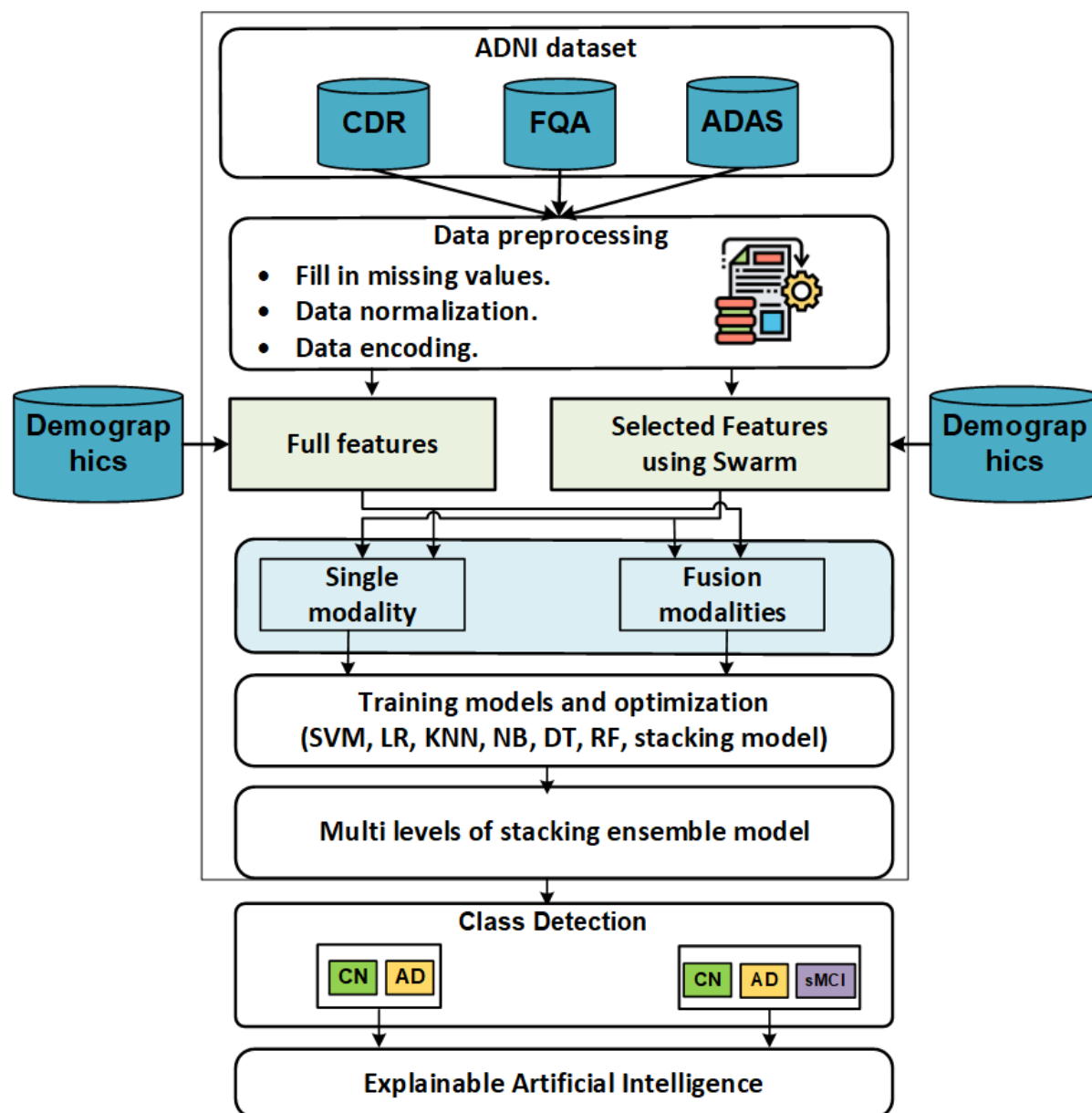


Fig 1: Single-Modal Data

Deep Learning Models on Image Datasets:

In contrast, some studies focused on employing Deep Learning (DL) models on image datasets. For instance, Islam et al. [65] employed a deep Convolutional Neural Network (CNN) for Alzheimer's diagnosis using brain MRI data, achieving significant improvements in multiclass classification. Rallabandi et al. [66] utilized a nonlinear SVM to classify various stages of cognitive impairment and AD based on whole-brain MRI scans. Moreover, using the ADNI dataset, researchers in [67] employed different ML models to discern distinctive aspects of AD staging, with the Generalized Linear Model (GLM) exhibiting the highest accuracy. Ahmed et al. [68] proposed a novel model utilizing Laplacian re-decomposition for picture fusion, achieving improved performance compared to traditional models such as NB, DT, SVM, and RF. Liu et al. [69] developed a multi-model deep CNN framework for automatic hippocampal segmentation and AD categorization, demonstrating promising results using T1-weighted sMRI data from the ADNI database.

Multimodal Data and ML/DL Models Integration:

Integrating heterogeneous multimodal data will enhance ML model performance and facilitate tailored decision-making. Tong et al. [70] applied ML models to different modalities (MRI and PET) to classify AD and MCI.

Lodha et al. [71] proposed 3D-CNN models for image fusion using MRI neuroimages to identify subjects with Alzheimer's. Additionally, ensemble learning techniques incorporating Random Forests (RF), Neural Networks (NN), and k-nearest Neighbors (KNN) were employed to increase AD and MCI detection accuracy [72]. Moreover, the role of RF in diagnosing AD with MRI images was investigated [73], and DL was applied to integrated MRI and PET image modalities for AD detection [74].

Utilizing Cognitive Scores for AD Detection:

Previous studies primarily focused on analyzing summary scores or image data for AD detection, overlooking the potential of cognitive scores (CSs) sub-scores. Therefore, our paper introduces a novel model-based three-level stacking approach utilizing CS sub-scores and their fusion to detect AD, considering both binary (AD vs. CN) and ternary (AD vs. CN vs. sMCI) classification. Furthermore, we employ explainable AI (XAI) techniques to interpret black box models for binary and ternary classification.

METHODS

A. Data Acquisition

Data for this study, the foundation of our research, were meticulously sourced from the Alzheimer's Disease Neuroimaging Initiative (ADNI) database, specifically from the initial phase (ADNI1). ADNI1 is a widely utilized resource for Alzheimer's disease (AD) diagnosis [28], [29]. The baseline ADNI1 dataset was acquired from a 1.5T Tesla scanner and pre-processed using Magnetization Prepared Rapid Gradient Echo (MP-RAGE) with a $256 \times 256 \times 170$ voxels resolution. Detailed information is available on the ADNI website. The dataset comprises 300 subjects categorized into AD (100 subjects), Mild Cognitive Impairment (MCI) (100 subjects), and Normal Control (NC) (100 subjects). This dataset size aligns with other studies employing machine learning for AD diagnosis [30], [31]. Notably, utilizing a smaller dataset reduces computational costs while maintaining diagnostic efficacy for AD [32].

B. Methodology

The classification of AD involved four critical steps conducted across three perspectives. Initially, data was retrieved from the ADNI database, followed by image extraction, slice selection, and the application of machine learning algorithms for multiclass classification. Figure 1 depicts a flowchart outlining the AD classification process.

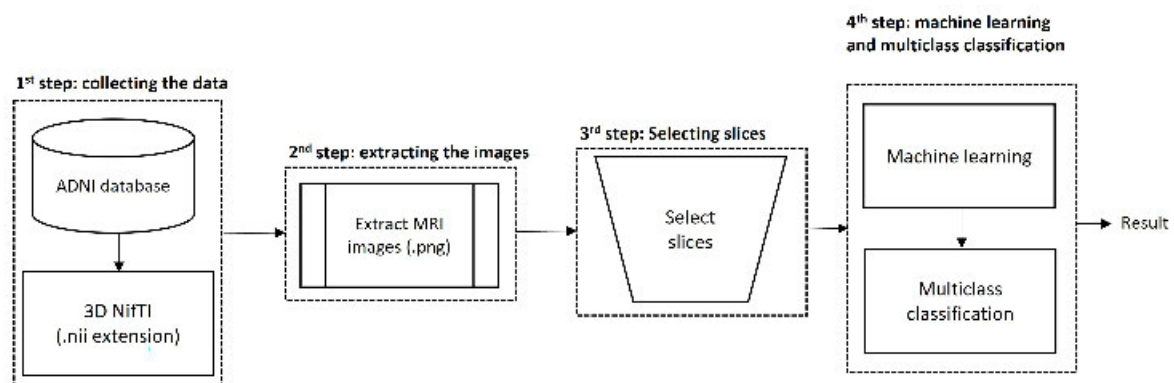


FIGURE 2. The flowchart illustrated the four steps for Alzheimer's disease (AD) classification.

1. Data Collection: Data was retrieved from the ADNI database in NifTI format, initially provided in 3D. Subsequently, the 3D NifTI files were converted to 2D images in PNG format to facilitate training, considering the computational intensity associated with 3D NifTI files [33].

The extracted images were categorized into AD, MCI, and NC groups across axial, coronal, and sagittal views. A slice selection method, guided by the expertise of medical professionals, was employed to choose relevant slices from the MRI image. These experts identified landmarks in the hippocampus region to select five slices per MRI image, ensuring the selection of the most informative slices for the study's classification process.

2. Classification Models: Two models, Resnet50 and LeNet, were utilized for AD classification. The classification process yielded multiclass results for AD, MCI, and NC categories.

The proposed slice selection method's performance was compared with that of using entire slices to ascertain its efficacy. Evaluation metrics included accuracy and model performance across different views and models.

C. Slice Selection Procedure

The slice selection process involved collaboration with medical experts from China Medical University Hospital, specializing in Neurology. The procedure comprised four steps:

1. Brain Region Identification: Medical experts reviewed MRI images across three views and categories to identify biomarkers indicative of AD, focusing on the hippocampus region.
2. Landmark-Based Slice Selection: Slices in MRI images were selected using landmarks within the hippocampus region across axial, coronal, and sagittal views.
3. Confirmation of Landmarks: Medical experts verified the selected MRI slices to ensure an accurate representation of the hippocampus region.
4. Dataset Recruitment: 300 subjects were recruited from the ADNI database, evenly distributed across AD, MCI, and NC categories. Each subject contributed approximately 160 to 170 MRI slices across three views, totalling 149,805 MRI slices. Five slices per view and category were selected from these, resulting in 500 MRI slices per view for 100 subjects.

The dataset was split into 80% training data (3,600 MRI slices) and 20% validation data (900 MRI slices) for model training and evaluation.

D. Convolutional Neural Network (CNN)

Recent advancements in machine learning, particularly convolutional neural networks (CNN), have demonstrated superior performance in AD classification [35]. In line with these advancements, two CNN models, Resnet50 and LeNet, were employed for AD classification, owing to their proven efficacy in previous studies [36], [37]. This use of cutting-edge technology instils confidence in the robustness of our methodology.

1. ResNet50:

- ResNet50, proposed by Chinese researchers, represents a significant advancement in CNN architecture [38]. With 50 layers organized into four stages, ResNet50 employs residual blocks to maintain model performance while increasing depth. Key features include ReLU activation, Max and Average Pooling layers for dimensionality reduction, and a SoftMax output layer for multiclass classification. Pretrained models have also been utilized for AD classification, although our implementation trained ResNet50 from scratch [40].

TABLE 1. The balanced dataset in each view and category for training and validation.

Categories	MRI view	Entire slices	Selecting slices	
			Training (80%)	Validation (20%)
AD (100 people)	Axial	~16,500*	400	100
	Coronal	~16,500*	400	100
	Sagittal	~16,500*	400	100
MCI (100 people)	Axial	~16,500*	400	100
	Coronal	~16,500*	400	100
	Sagittal	~16,500*	400	100
NC (100 people)	Axial	~16,500*	400	100
	Coronal	~16,500*	400	100
	Sagittal	~16,500*	400	100
Summary		149,805	3600	900

The architecture of Resnet50 is illustrated in Figure 4.

2) LeNet

The LeNet architecture, initially developed by LeCun et al. [41], stands as one of the earliest and simplest models in neural networks. Renowned for its efficiency, LeNet requires relatively less computational time, making it a preferred choice for various image classification tasks [42]. Notably, it excels in medical image classification [43], boasting over 92% accuracy in distinguishing conditions like Alzheimer's disease (AD) [44]. While primarily tailored for classification tasks, this study leverages the LeNet model specifically for AD classification, as depicted in Figure 5.

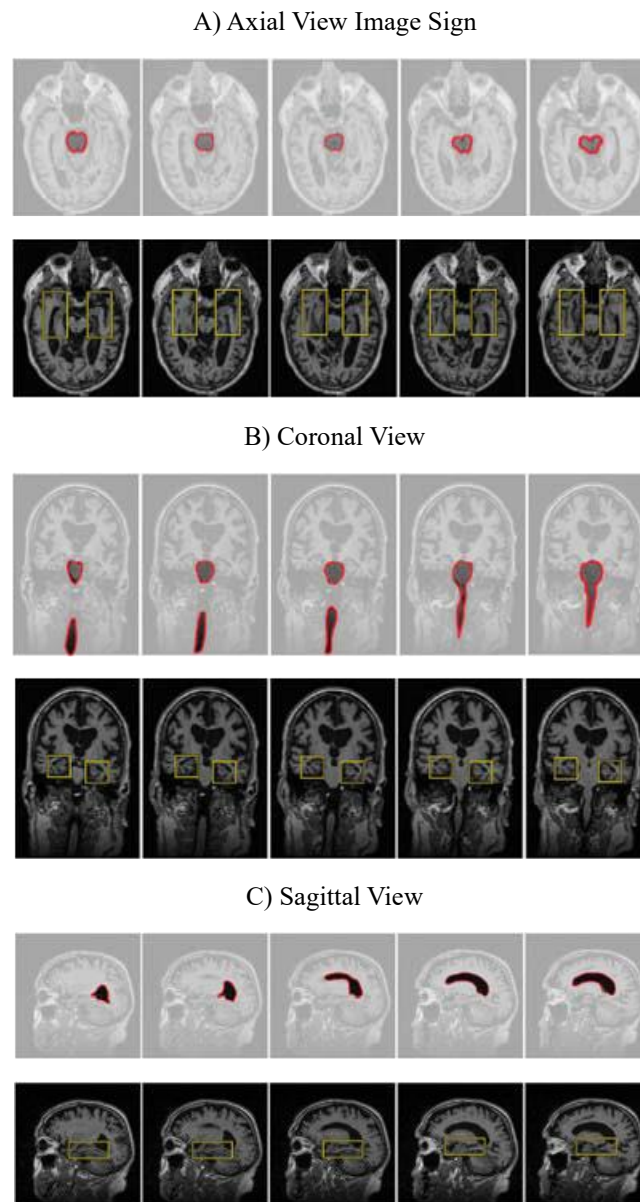


FIGURE 3. the strategy for choosing MRI image slices that makes use of the hippocampal landmarks in three different viewpoints and categories; (A) An imaging sign indicates the hippocampus from the axial midbrain inferior part (also known as the "mickey mouse sign") to the upper part (also known as the "apple sign"); (B) An imaging sign indicates the hippocampus from the brainstem anterior part to the entire brainstem visible; (C) An imaging sign indicates the hippocampus from a sagittal view in the ventricles lateral; and (D) An imaging sign indicates the hippocampus region.

RESULTS

All experiments in our study were conducted using the same dataset. We employed two models, namely Resnet50 and LeNet, for multiclass classification (AD, MCI, and NC) across three views (axial, coronal, and sagittal). The details of our investigation are outlined below.

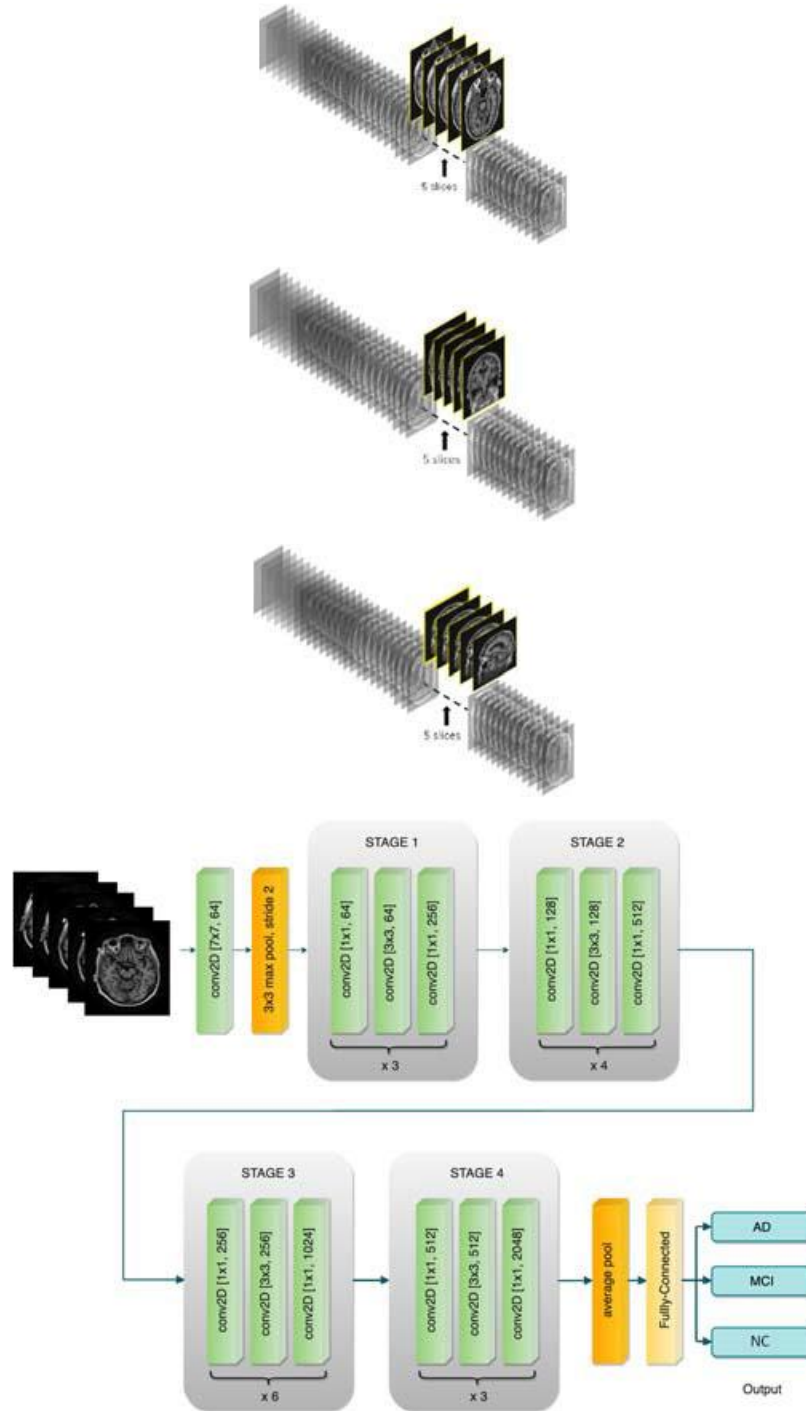


FIGURE 4: a thorough process for choosing five slices out of each complete slice on the MRI pictures; Slice selection in axial view (A); coronal view (B); and axial view (C).

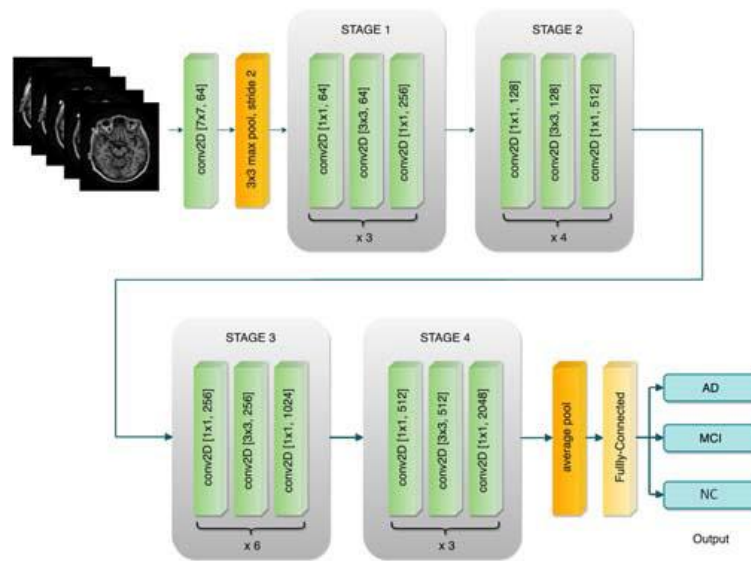


FIGURE 5. The Resnet50 architecture; Note: Normal Control (NC), Mild Cognitive Impairment (MCI), Alzheimer's Disease (AD).

A. Impact of Slice Selection

Table 2 provides a clear picture of the accuracy of the proposed slice selection method. A comparison was then made between the use of entire slices on MRI images and the application of the slice selection method. This was done to evaluate their effectiveness and performance across three views and three categories. The results, as shown in Table 2, are unambiguous. The slice selection method demonstrated superior accuracy, ranging from 0.84 to 0.98 across the two models, compared to using entire slices on MRI images. In contrast, the use of entire slices resulted in lower accuracy, ranging from 0.37 to 0.65 across the two models. These findings underscore the reliability of the slice selection method in the context of medical imaging.

B. Comparison of Three Perspectives

To assess the accuracy of each perspective, comparisons were made among them by selecting slices based on landmark positioning within the hippocampus region. As depicted in Figure 6(B), the coronal perspective exhibited superior accuracy compared to the other two. Specifically, the accuracy recorded in the coronal perspective was 0.97, 0.95, and 0.98 for the pre-trained Resnet50, Resnet50, and LeNet models. Conversely, the axial perspective showed accuracies of 0.98, 0.84, and 0.98, while the sagittal perspective showed accuracies of 0.95, 0.94, and 0.97 for the same models. Additionally, the average accuracy in the coronal perspective, as indicated in Table 1, was notably higher at 0.96.

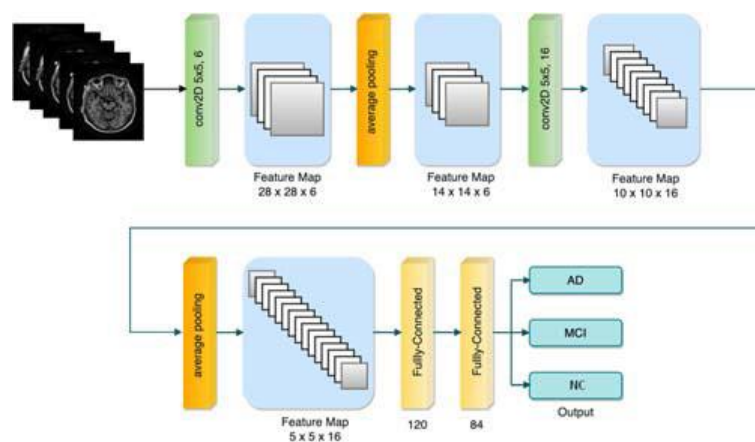


FIGURE 6. The LeNet architecture; Note: Normal Control (NC), Mild Cognitive Impairment (MCI), Alzheimer's Disease (AD).

TABLE 2. The accuracy comparison between the entire slices and the selecting slices method.

Accuracy	Entire slices			Selecting slices		
	Axial	Coronal	Sagittal	Axial	Coronal	Sagittal
Pretrained Resnet50	0.52	0.45	0.65	0.98	0.97	0.95
Resnet50	0.45	0.37	0.55	0.84	0.95	0.94
LeNet	0.65	0.37	0.58	0.98	0.98	0.97
Average accuracy	0.54	0.39	0.59	0.93	0.96	0.95

C. Comparison of Two Models

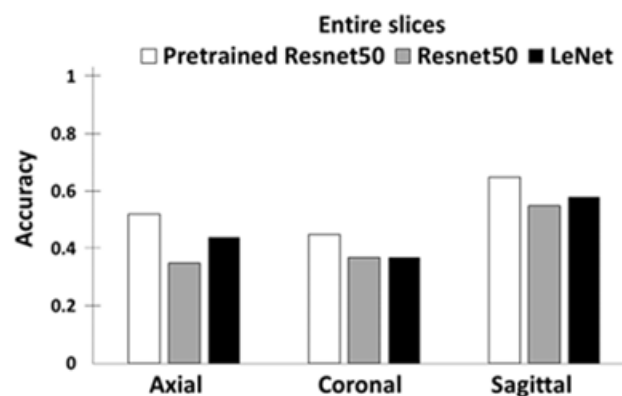
The two models were compared to determine which yielded better performance in Alzheimer's disease (AD) classification. As per Table 2, it was observed that the LeNet model demonstrated superior comprehensive performance across the three perspectives. Notably, the LeNet model exhibited more significant accuracy gains across all perspectives than the other model variants. The accuracies of the LeNet model were recorded as 0.98 in the axial perspective, 0.98 in the coronal perspective, and 0.97 in the sagittal perspective.

D. Performance of Multiclass Classification

The performance evaluation of multiclass classification aimed to ascertain the precision, recall, and F1 scores across three categories: Alzheimer's disease (AD), Mild Cognitive Impairment (MCI), and Normal Control (NC). According to Table 3, the multiclass classification results for AD, MCI, and NC in the coronal and sagittal perspectives demonstrated superior precision, recall, and F1 scores, ranging from 0.90 to 1.00, particularly evident in the pre-trained Resnet50 and LeNet models. In contrast, MCI classification in the axial perspective exhibited comparatively lower scores, ranging from 0.81 to 0.88 for the Resnet50 model.

DISCUSSION

The research showcased the efficacy of the selecting slices method in enhancing machine learning performance for Alzheimer's Disease (AD) classification using MRI data. This finding supports our hypothesis, suggesting that the proposed selecting slices approach outperforms utilizing entire MRI slices for AD classification. Notably, the selecting slices method demonstrated superior accuracy in the coronal view compared to the axial and sagittal views. However, it's noteworthy that the LeNet model outperformed Resnet50 in this study. Additionally, the multiclass classification results shed light on the significance of each category across the three views.



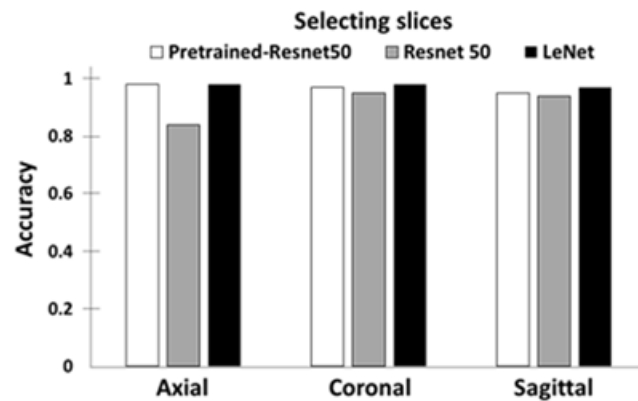


FIGURE 7. The accuracy graph performance in AD classification; (A) Entire slices; (B) Selecting slices method.

TABLE 3. The Precision, Recall, and F1 Score for multiclass classification.

Model	Class	Model performance								
		Precision			Recall			F1 score		
		axial	coronal	sagittal	axial	coronal	sagittal	axial	coronal	sagittal
Pretrained-Resnet50	AD	0.98	0.97	0.92	0.99	0.96	0.95	0.99	0.96	0.94
	MCI	0.98	0.97	0.95	0.97	0.96	0.93	0.97	0.96	0.94
	NC	0.99	0.97	0.99	0.99	0.99	0.98	0.99	0.98	0.98
Resnet50	AD	0.87	0.92	0.90	0.89	0.98	0.94	0.88	0.95	0.92
	MCI	0.81	0.97	0.98	0.82	0.92	0.90	0.82	0.94	0.94
	NC	0.82	0.97	0.95	0.80	0.96	0.99	0.81	0.96	0.97
LeNet	AD	1.00	0.99	0.97	1.00	0.97	0.94	1.00	0.98	0.95
	MCI	0.96	0.97	0.96	0.99	0.99	0.97	0.98	0.98	0.97
	NC	0.99	1.00	0.98	0.96	1.00	1.00	0.97	1.00	0.99

Our findings indicate that employing the selecting slices method, mainly focusing on landmarks in the hippocampus region, leads to higher accuracy than using entire slices in MRI images. This aligns with prior research, which suggests that selecting slices from the specific areas within MRI images can enhance AD classification performance. Notably, our approach achieved higher accuracy without additional computational processes on MRI images, highlighting its efficiency.

Our approach demonstrated superior performance by comparing our proposed method with existing literature (see Table 4). Notably, it outperformed various models used in previous studies across different views and models, emphasizing its effectiveness despite its simplicity.

TABLE 4. The comparison results with other studies

Study	Model	Dataset	Accuracy		
			Axial	Coronal	Sagittal
	(Method)				
Valliani et al. [47]	Pretrained Resnet (Augmentation)	-	0.56	-	-
Angkoso et al. [45]	CNN (BET)	ADNI	0.86	0.85	0.85
Altaf et al. [48]	KNN (GLCM, Segmented region)	ADNI	0.79	-	-
Shi et al. [49]	Conv-LSTM	MNIST	0.59	0.57	0.52
Current Study	Pretrained Resnet50	ADNI	0.98	0.97	0.95
	Resnet50		0.84	0.95	0.94
	LeNet		0.98	0.98	0.97

Analysis of the LeNet model's performance revealed higher accuracy in the coronal view, suggesting that this view may contain crucial information about hippocampal landmarks, vital for early AD detection. This finding corroborates previous research indicating the discriminative nature of the hippocampus region in the coronal view. Thus, utilizing the coronal view in MRI images may enhance early AD detection, which is consistent with medical experts' practices.

Moreover, the LeNet model consistently showed higher accuracy across all views, indicating its efficacy in training MRI images for classification tasks. Its simple yet effective architecture makes it a suitable choice for such tasks, as evidenced by its performance in this study.

While Pretrained Resnet50 exhibited decent performance, it was surpassed by LeNet in terms of accuracy. This may be attributed to the pretraining process, where Resnet50 initializes weights from a larger benchmark dataset like Imagenet. Nonetheless, leveraging pretraining can enhance model convergence, particularly with smaller datasets.

Additionally, the study highlights the challenge of classifying Mild Cognitive Impairment (MCI), which showed lower precision, recall, and F1 score, indicating its subtle structural changes and high misdiagnosis probability compared to AD and Normal Control (NC) categories.

Despite the study's contributions, several limitations exist. Manually selecting slices from MRI images was labor-intensive and could be replaced with automated methods utilizing deep learning. Similarly, the absence of data augmentation might have affected model performance, suggesting a potential avenue for improvement in future studies.

CONCLUSION

In conclusion, this study demonstrates the efficacy of selecting slices in enhancing machine learning performance for AD classification using MRI data. The coronal view proved particularly informative, and the LeNet model exhibited superior performance. Multiclass classification results provide insights into the value of each category for AD classification. However, future research should address limitations such as manual slice selection and lack of data augmentation to enhance accuracy and efficiency further.

REFERENCES

1. Alzheimer's Association, "2017 Alzheimer's disease facts and figures," *Alzheimer's Dementia*, vol. 13, no. 4, pp. 325–373, Apr. 2017, doi: [10.1016/j.jalz.2017.02.001](https://doi.org/10.1016/j.jalz.2017.02.001).
2. G. Livingston, J. Huntley, A. Sommerlad, D. Ames, C. Ballard, and S. Banerjee, "Dementia prevention, intervention, and care: 2020 report of the Lancet commission," *Lancet*, vol. 396, no. 10248, pp. 413–446, 2020, doi: [10.1016/S0140-6736\(20\)30367-6](https://doi.org/10.1016/S0140-6736(20)30367-6).
3. G. B. Frisoni, N. C. Fox, C. R. Jack, P. Scheltens, and P. M. Thompson, "The clinical use of structural MRI in Alzheimer disease," *Nature Rev. Neurol.*, vol. 6, no. 2, pp. 67–77, Feb. 2010, doi: [10.1038/nrneurol.2009.215](https://doi.org/10.1038/nrneurol.2009.215).

4. J. Olloquequi, M. Etcheto, A. Cano, E. Sanchez-López, M. Carrasco, T. Espinosa, C. Beas-Zarate, G. Gudiño-Cabrera, M. E. Ureña-Guerrero, E. Verdaguer, J. Folch, C. Auladell, and A. Camins, "Impact of new drugs for therapeutic intervention in Alzheimer's disease," *Frontiers Bioscience-Landmark*, vol. 27, no. 5, p. 146, 2022, doi: [10.31083/j.fbl2705146](https://doi.org/10.31083/j.fbl2705146).
5. Y. L. Rao, B. Ganaraja, B. V. Murlimanju, T. Joy, A. Krishnamurthy, and A. Agrawal, "Hippocampus and its involvement in Alzheimer's disease: A review," *3 Biotech*, vol. 12, no. 2, pp. 1–10, Feb. 2022, doi: [10.1007/s13205-022-03123-4](https://doi.org/10.1007/s13205-022-03123-4).
6. M. Laakso, "MRI of hippocampus in incipient Alzheimer's disease," Ph.D. dissertation, Ser. Rep. Dept. Neurol., Univ. Kuopio, Kuopio, Finland, 1996.
7. A. Moscoso, J. Silva-Rodríguez, J. M. Aldrey, J. Cortés, A. Fernández-Ferreiro, N. Gómez-Lado, Á. Ruibal, and P. Aguiar, "Prediction of Alzheimer's disease dementia with MRI beyond the short-term: Implications for the design of predictive models," *NeuroImage, Clin.*, vol. 23, Jan. 2019, Art. no. 101837, doi: [10.1016/j.nicl.2019.101837](https://doi.org/10.1016/j.nicl.2019.101837).
8. K. M. Poloni and R. J. Ferrari, "Automated detection, selection and classification of hippocampal landmark points for the diagnosis of Alzheimer's disease," *Comput. Methods Programs Biomed.*, vol. 214, Feb. 2022, Art. no. 106581, doi: [10.1016/j.cmpb.2021.106581](https://doi.org/10.1016/j.cmpb.2021.106581).
9. A. Demirhan, "Classification of structural MRI for detecting Alzheimer's disease," *Int. J. Intell. Syst. Appl. Eng.*, vol. 4, no. 1, pp. 195–198, Dec. 2016.
10. H. Qiao, L. Chen, Z. Ye, and F. Zhu, "Early Alzheimer's disease diagnosis with the contrastive loss using paired structural MRIs," *Comput. Methods Programs Biomed.*, vol. 208, Sep. 2021, Art. no. 106282, doi: [10.1016/j.cmpb.2021.106282](https://doi.org/10.1016/j.cmpb.2021.106282).
11. S. Savaş, "Detecting the stages of Alzheimer's disease with pre-trained deep learning architectures," *Arabian J. Sci. Eng.*, vol. 47, no. 2, pp. 2201–2218, 2022.
12. Z. Zhang and E. Sejdić, "Radiological images and machine learning: Trends, perspectives, and prospects," *Comput. Biol. Med.*, vol. 108, pp. 354–370, May 2019, doi: [10.1016/j.compbiomed.2019.02.017](https://doi.org/10.1016/j.compbiomed.2019.02.017).
13. Y. Kazemi and S. Houghten, "A deep learning pipeline to classify different stages of Alzheimer's disease from fMRI data," in *Proc. IEEE Conf. Comput. Intell. Bioinf. Comput. Biol. (CIBCB)*, May 2018, pp. 1–8, doi: [10.1109/CIBCB.2018.8404980](https://doi.org/10.1109/CIBCB.2018.8404980).
14. S. Gao and D. Lima, "A review of the application of deep learning in the detection of Alzheimer's disease," *Int. J. Cognit. Comput. Eng.*, vol. 3, pp. 1–8, Jun. 2022, doi: [10.1016/j.ijcce.2021.12.002](https://doi.org/10.1016/j.ijcce.2021.12.002).
15. E. Thibeau-Sutre, B. Couvy-Duchesne, D. Dormont, O. Colliot, and N. Burgos, "MRI field strength predicts Alzheimer's disease: A case example of bias in the ADNI data set," in *Proc. IEEE 19th Int. Symp. Biomed. Imag. (ISBI)*, Mar. 2022, pp. 1–4, doi: [10.1109/ISBI52829.2022.9761504](https://doi.org/10.1109/ISBI52829.2022.9761504).
16. M. Raju, V. P. Gopi, and V. S. Anitha, "Multi-class classification of Alzheimer's disease using 3DCNN features and multilayer perceptron," in *Proc. 6th Int. Conf. Wireless Commun., Signal Process. Netw. (WiSPNET)*, Mar. 2021, pp. 368–373, doi: [10.1109/WiSPNET51692.2021.9419393](https://doi.org/10.1109/WiSPNET51692.2021.9419393).
17. V. Sathiyamoorthi, A. K. Ilavarasi, K. Murugeswari, S. T. Ahmed, B. A. Devi, and M. Kalipindi, "A deep convolutional neural network based computer aided diagnosis system for the prediction of Alzheimer's disease in MRI images," *Measurement*, vol. 171, Feb. 2021, Art. no. 108838, doi: [10.1016/j.measurement.2020.108838](https://doi.org/10.1016/j.measurement.2020.108838).
18. N. Yamanakkanavar, J. Y. Choi, and B. Lee, "MRI segmentation and classification of human brain using deep learning for diagnosis of Alzheimer's disease: A survey," *Sensors*, vol. 20, no. 11, p. 3243, Jun. 2020, doi: [10.3390/s20113243](https://doi.org/10.3390/s20113243).
19. M. Karthiga, S. Sountharajan, S. Nandhini, and B. S. Kumar, "Machine learning based diagnosis of Alzheimer's disease," in *Proc. Int. Conf. Image Process. Capsule Netw. Cham, Switzerland: Springer*, 2020, pp. 607–619, doi: [10.1007/978-3-030-51859-2_55](https://doi.org/10.1007/978-3-030-51859-2_55).
20. A. Farooq, S. Anwar, M. Awais, and S. Rehman, "A deep CNN based multi-class classification of Alzheimer's disease using MRI," in *Proc. IEEE Int. Conf. Imag. Syst. Techn. (IST)*, Oct. 2017, pp. 1–6, doi: [10.1109/IST.2017.8261460](https://doi.org/10.1109/IST.2017.8261460).